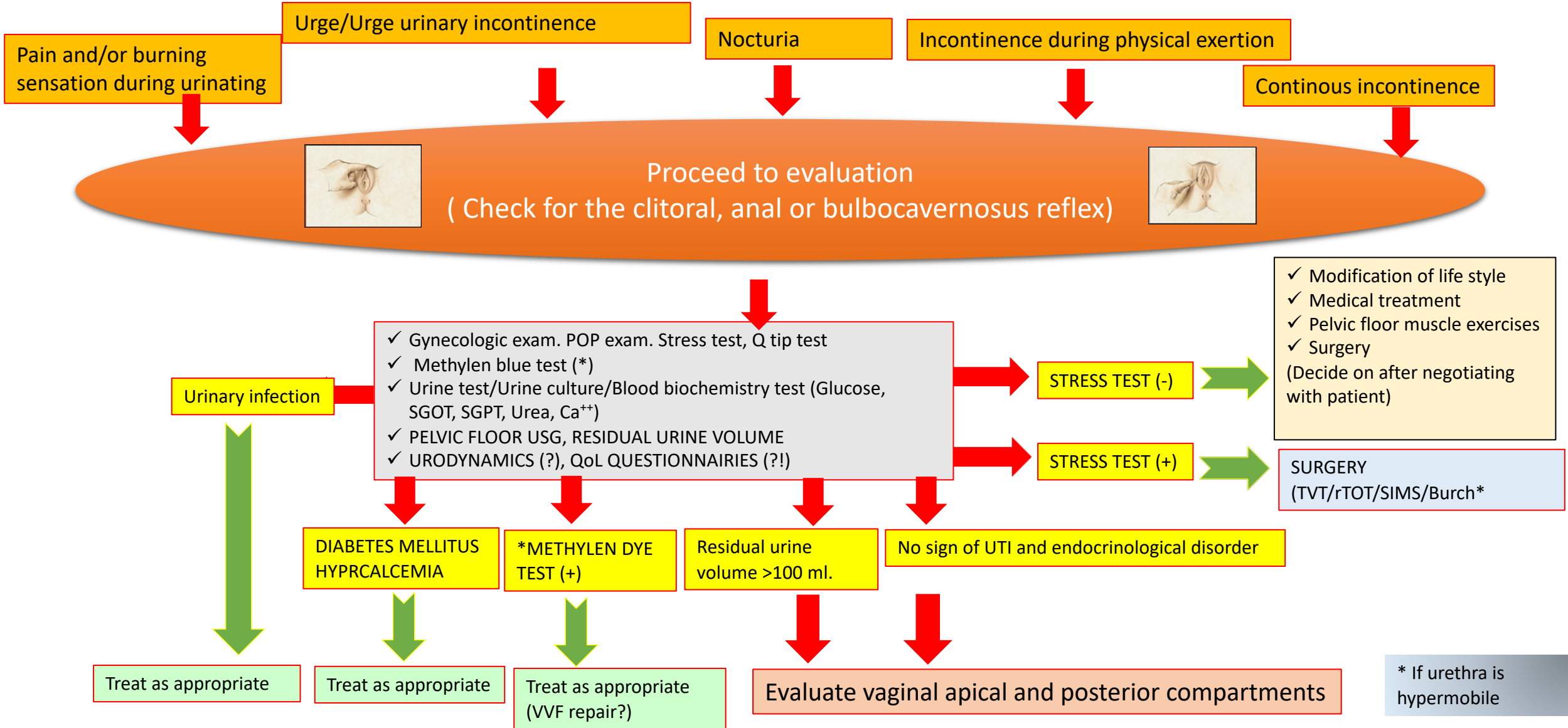
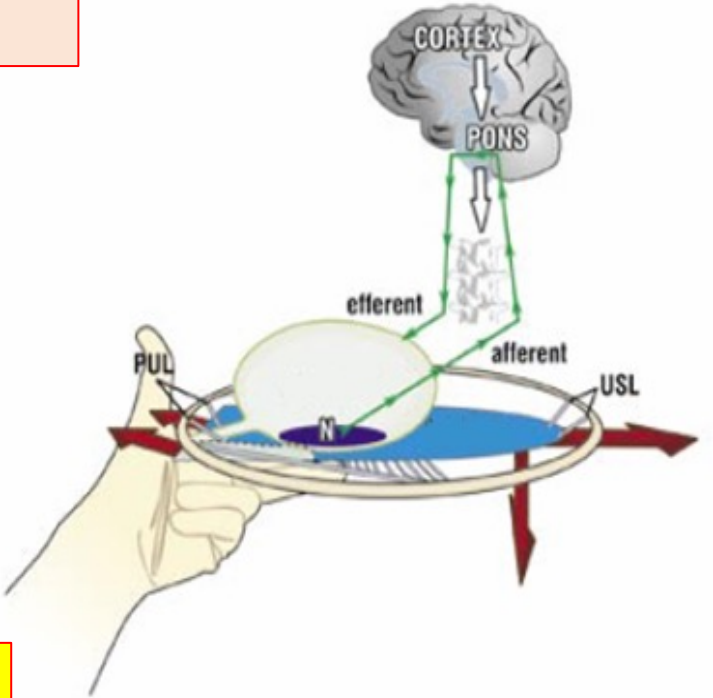
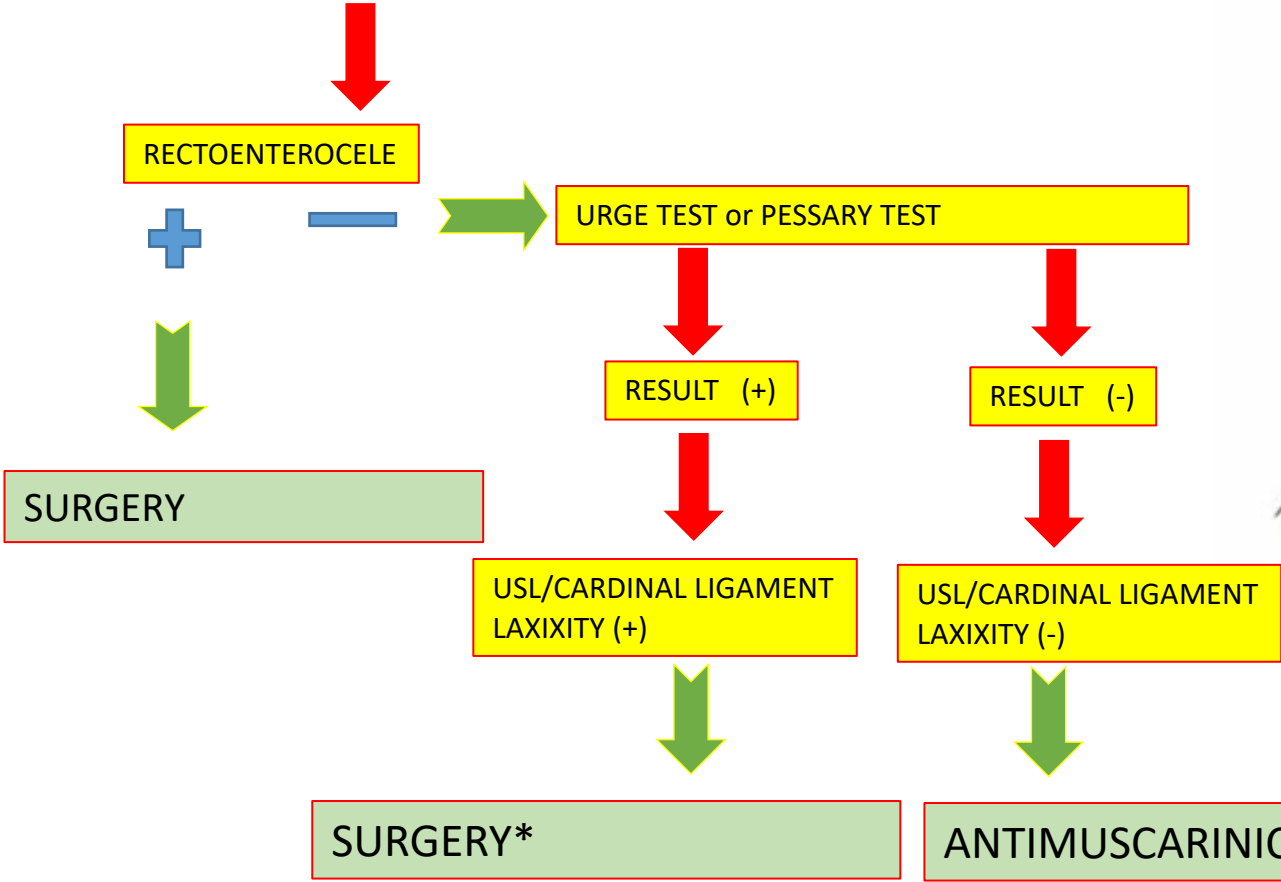


# SIVASLIOGLU'S INCONTINENCE FLOW CHART BASED ON THE INTEGRAL SYSTEM



\* If urethra is hypermobile

# EVALUATION OF VAGINAL APICAL AND POSTERIOR COMPARTMENTS



\*In younger patients: Plication of USLs.  
In older patients: Posterior IVS.